

See discussions, stats, and author profiles for this publication at: <https://www.researchgate.net/publication/321690718>

Fetal development of the Poeypig's woolly monkey (*Lagothrix poeypigii*)

Article in *Theriogenology* · April 2018

DOI: 10.1016/j.theriogenology.2017.12.022

CITATIONS

0

READS

34

6 authors, including:



Frederico Ozanan Barros Monteiro

Universidade Federal Rural da Amazônia (UF...)

66 PUBLICATIONS 165 CITATIONS

[SEE PROFILE](#)



Hani Rocha El Bizri

Instituto de Desenvolvimento Sustentável M...

24 PUBLICATIONS 53 CITATIONS

[SEE PROFILE](#)



Diva Anelie Guimarães

Federal University of Pará

44 PUBLICATIONS 240 CITATIONS

[SEE PROFILE](#)



Pedro Mayor

Autonomous University of Barcelona

59 PUBLICATIONS 379 CITATIONS

[SEE PROFILE](#)

Some of the authors of this publication are also working on these related projects:



Health of species under wildlife production [View project](#)



Reproductive physiology of Neotropical Primates in the Amazon region [View project](#)

All content following this page was uploaded by [Hani Rocha El Bizri](#) on 22 January 2018.

The user has requested enhancement of the downloaded file.



Fetal development of the Poeppig's woolly monkey (*Lagothrix poeppigii*)

Rafael dos Santos de Andrade ^a, Frederico Ozanan Barros Monteiro ^{a,*},
Hani Rocha El Bizri ^{b,c}, Wilter Ricardo Russiano Vicente ^a,
Diva Anelie de Araujo Guimarães ^d, Pedro Mayor ^{a,e}

^a Federal Rural University of the Amazon (UFRA), Postgraduate Program in Animal Health and Production in Amazonia (PPGSPAA), Belém, PA, Brazil

^b Manchester Metropolitan University, School of Science and the Environment, Manchester, United Kingdom

^c Mamirauá Institute for Sustainable Development (IDSMD), Tefé, AM, Brazil

^d Federal University of Pará (UFPA), Institute of Biological Sciences, Belém, PA, Brazil

^e Universitat Autònoma de Barcelona (UAB), Departament de Sanitat i d'Anatomia Animals, Facultat de Veterinària, Barcelona, Spain

ARTICLE INFO

Article history:

Received 10 September 2017

Received in revised form

2 December 2017

Accepted 7 December 2017

Available online 8 December 2017

Keywords:

Woolly monkey

Reproduction

Fetal features

Gestational development

Amazon

ABSTRACT

The intrauterine development is an evolutionary strategy that prepares the neonate for extra-uterine life, thus providing important information on the life history of species. In this study, we described the external and internal morphology of 25 fetuses of Poeppig's woolly monkeys (*Lagothrix poeppigii*) by taking advantage of a 10-year participatory collection of biological samples originated from animals hunted for subsistence purposes in the Peruvian Amazon. Logistic regressions estimated the probability of occurrence of each external morphological characteristic in relation to the crown-rump length (CRL). The presence of nails, closed eyelids, differentiated genitalia and formed limbs with separation of the digits were observed in all analyzed fetuses (≥ 4.2 cm CRL). The other characteristics appeared in the following order: skin with epidermal pigmentation, oral and nasal mucosal pigmentation, tactile pelage and covering pelage. Although advanced fetuses (> 15.8 cm CRL) showed most fetal external characteristics, they were not fully developed and no specimen showed tooth eruption or opened eyelids. The growth formula used to determine fetal age was $\forall W = 0.042 (t - 45)$, with a high linear relationship between CRL and gestational age. All associations between the external biometry, absolute volume of internal organs and the CRL had a high coefficient of determination. Advanced fetuses and adults showed similar relative volume of thoracic and abdominal organs, except for thymus and the liver with a higher and lower relative volume, respectively. The relative volume of the tubular gastrointestinal tract and the thymus had a constant increase along fetal development, and the liver showed a significant decrease. This study describes important morphological events for understanding the gestational development in the *Lagothrix* genus. In addition, these results may be useful to improve imaging techniques, contributing to the *in situ* and *ex situ* reproductive management of this highly hunted species in the Amazon.

© 2017 Elsevier Inc. All rights reserved.

1. Introduction

The Poeppig's woolly monkey (*Lagothrix poeppigii*, Atelidae) is the most frequently hunted Neotropical primate in the Amazon region, especially due to its large body size (7 kg), and is considered

* Corresponding author. Programa de Pós-graduação em Saúde e Produção Animal na Amazônia, Universidade Federal Rural da Amazônia, Avenida Presidente Tancredo Neves, N° 2501 Bairro: Terra Firme Cep: 66.077-830, Belém, Pará, Brazil.

E-mail addresses: frederico.monteiro@ufra.edu.br, fredericovet@hotmail.com (F.O.B. Monteiro).

vulnerable by the IUCN [1]. Although reproductive information can provide clues for the development of conservation strategies, data on woolly monkey reproduction are still scarce, and most studies have been conducted under captive conditions. The captive woolly monkey has a long gestation period (225 days), late puberty (at 4–5 years), and one young per birth on average [2]. The infants are born with approximately 10% of the mother's weight and show a long weaning period of 12–24 months [3,4]. In the Peruvian Amazon, the Poeppig's woolly monkey in the wild produces 0.48–0.54 offspring per female per year, and has an interbirth interval of 22.3–25.2 months [5].

Imaging techniques are vital for developing appropriate reproductive management practices in wild species, improving pregnancy diagnosis, parturition prediction, and the determination of malformations and viability of fetuses [6,7]. Previous studies have reported the successful use of imaging techniques to conduct fetal measurements and characterization in captive primates, such as in the genera *Pan*, *Gorilla*, *Mandrillus*, *Erythrocebus* and *Macaca* [8–11]. However, the reliable standardization of fetal measurements for applying imaging techniques in most Neotropical primates, except for the genus *Sapajus* [12], has been hampered due to insufficient number of samples. To our knowledge, these measurements have never been conducted in the woolly monkey, since the species' high susceptibility to diseases [2] and low reproductive efficiency [13] make it difficult to sustain captive populations.

The use of pregnant reproductive tracts from animals hunted for subsistence purposes, through collaborative methods with local communities, represents an alternative for *in situ* biological collection of a large sample size. This sampling strategy allows for the utilization of embryos and fetuses that would be otherwise discarded by the locals [14]. The present study aimed to describe the fetal development of the wild Poeppig's woolly monkey, by taking advantage of a 10-year participatory collection of biological samples originated from subsistence hunting activity in the Peruvian Amazon.

2. Material and methods

This study was conducted in the Yavari-Mirín River, in the Northeastern Peruvian Amazon, a continuous area of 107,000 ha of predominantly non-flooded upland forest. The temperature in this region ranges from 22° to 36 °C, with an annual precipitation of 1500–3000 mm. Nueva Esperanza (S 04°19.53 W 71°57.33) is the only indigenous community in the study area, with 307 inhabitants. Local residents rely on agriculture, fishing, logging, and hunting for subsistence.

2.1. Biological sample collection and processing

From 2005 to 2014, hunters living in the study area voluntarily donated genital organs from 25 hunted pregnant Poeppig's woolly monkeys. During the study, we trained hunters to remove all abdominal and pelvic organs complete with the perineal region and store these in buffered 4% formaldehyde solution (v/v). Since we collected only unconsumed organs, we assured that no additional mortality of woolly monkeys was incurred for the purpose of this study.

Genital organs were dissected to remove all conceptuses. The 25 *Lagothrix poeppigii* fetuses obtained were analyzed [15]. First, a description of the external morphological features was conducted by searching for the presence and overtone of eyelids, tooth eruption, presence of skin, nails, tactile and covering pelage, dermal and oral/nasal mucosal pigmentation, and genitalia and limb buds. The fetal stage was determined and all feature nomenclatures were based on the *International Committee on Veterinary Embryological Nomenclature* [16].

This research was evaluated and approved by the Ethics Committee for Experimentation from the Servicio Nacional Forestal y de Fauna Silvestre of Peru (protocol number 0350-2012-DGFFS-DGEFFS). Samples were sent to Federal Rural University of the Amazon (UFRA), Belém, Pará, Brazil, through the export license CITES/IBAMA (N° 14BR015991/DF). No animal was killed specifically for the research and hunters were not paid for the sample collection.

External biometric measurements were performed in 23 fetuses, since two specimens were flattened and were excluded. The

measurements included body mass, crown-rump length (CRL), total dorsal length, biparietal diameter (BPD), occipital-frontal diameter (OFD), cranial circumference (CC), femur and humerus length (FL and HL), length of thoracic and pelvic limbs (TL and PL), thoracic diameter and circumference (TD and TC), as well as abdominal diameter and circumference (AD and AC). Thoracic and abdominal measurements were obtained from the last rib and the insertion of the umbilical cord, respectively. The body mass was measured in grams using a digital weighting scale (0.1 g accuracy), and a tape measure (0.1 mm accuracy) and a metal caliper (full measurement capability 300 mm) were employed for body measurements.

All fetuses were dissected to calculate the volume of thoracic and abdominal organs fetal organs, including the heart, lungs, liver, spleen, kidneys, tubular gastrointestinal tract, and thymus. Seven fetuses with signs of visceral autolysis were discarded from this analysis. Volumetric measurements were conducted by submerging the organs in hypodermic syringes with 0.01 ml accuracy filled with water and applying the Archimedes Principle [15], considering the value of water volume displaced as a proxy of the organ volume. The summative volume of all organs was considered as the total visceral volume. The relative volume of each fetal organ was calculated as a percentage respective to the total visceral volume. In parallel, the volume of the same organs was also measured in 13 adult Poeppig's woolly monkeys hunted in the same study area to compare the relative volume of fetal organs in advanced pregnancy stage with that in adults.

2.2. Statistical analysis

Logistic regressions were applied to estimate the probability of occurrence of each external morphological characteristic in relation to the CRL using the software Statistica 8.0 (StatSoft Inc., Tulsa, USA). Multiple regression modeling between the studied biometric measures, organ volumes and CRL were performed using the software CurveExpert 2.4 (© Copyright 2017, Daniel G. Hyams) to define those functions that were best fitted to the plots. Regressions were also used to assess allometric relationships between the BPD and OFD; TC and AC; HL and FL; TL and PL. For absolute measurements,

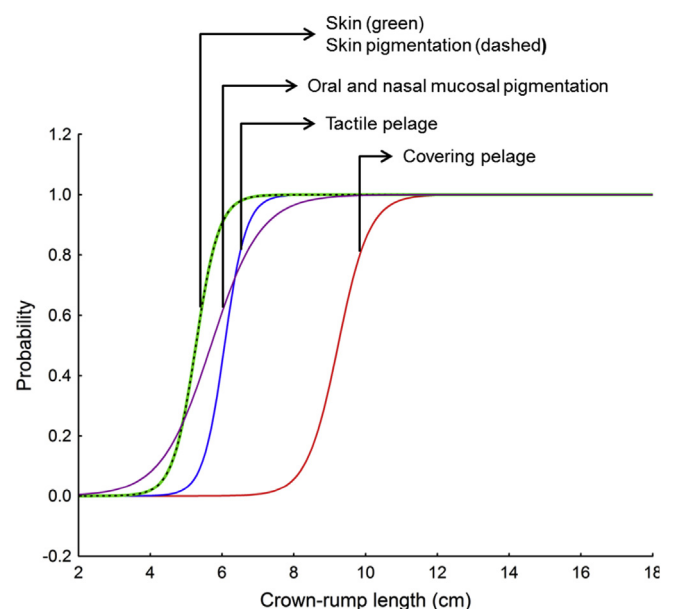


Fig. 1. Probability curves for morphological features along the increase in crown-rump length (CRL) in 25 fetuses of the Poeppig's woolly monkey (*Lagothrix poeppigii*).

Table 1Logistic equations of the external morphological features parameters in 25 Poeppig's woolly monkey (*Lagothrix poeppigii*) fetuses.

Morphological features	Equation	Chi-square (Df)	P value
Dermis	$y = \frac{2.72(-16.342 + (3.10132)^x)}{1 + 2.72(-16.342 + (3.10132)^x)}$	11.45 (1)	<0.01
Dermal pigmentation	$y = \frac{2.72(-16.342 + (3.10132)^x)}{1 + 2.72(-16.342 + (3.10132)^x)}$	11.45 (1)	<0.01
Mucosal pigmentation	$y = \frac{2.72(-8.2166 + (1.44394)^x)}{1 + 2.72(-8.2166 + (1.44394)^x)}$	20.09 (1)	<0.01
Tactile pelage	$y = \frac{2.72(-20.21 + (3.33067)^x)}{1 + 2.72(-20.21 + (3.33067)^x)}$	18.57 (1)	<0.01
Covering pelage	$y = \frac{2.72(-21.126 + (2.28893)^x)}{1 + 2.72(-21.126 + (2.28893)^x)}$	25.29 (1)	<0.01

we forced linear regressions to origin and only considered those functions with a starting point on or near zero, since we expected both internal and external measurements to be zero on day 0 of fetal development.

The fetal age was estimated using the formula proposed by Huggett and Widdas [17], $\sqrt[3]{W} = a(t - t_0)$, where W is the fetal weight, a is the specific fetal growth velocity, t is the fetal age in days, and t_0 is the calculated interception on the age axis. According to those authors, t_0 is equal to 20% of gestation time in species that present between 100 and 400 days of pregnancy. To use that equation, we considered a gestation length of 225 days [2], and a mean weight of 450 g for pre-partum fetuses, taking into account the weight stabilization in fetuses in more advanced stages of gestation (CRL > 15.8 cm).

We compared the relative volumes of visceral organs of larger fetuses (>15.0 cm CRL) with those of adults by means of T tests. Differences with a probability value of 0.05 or lower ($p < 0.05$) were considered significant. All descriptive values of fetal measurements are expressed as the mean \pm standard deviation (SD).

3. Results

In the studied fetuses, the average CRL was 10.1 ± 3.7 SD cm, ranging from 4.2 to 17.3 cm, and the average body mass was 129.1 ± 143.8 SD g, ranging from 7 to 500 g. Fig. 1 shows the probability curves for the occurrence of external morphological features according to CRL, while Table 1 shows the regression models. The presence of nails, closed eyelids, differentiated genitalia (14 females and 11 males) and formed limbs with separation of the digits was observed in all analyzed fetuses (≥ 4.2 cm CRL). Fetuses with a CRL of 5.2 cm showed the first signs of skin with epidermal pigmentation, and oral and nasal mucosal pigmentation. Tactile pelage was first observed in fetuses with a CRL of 6.5 cm. All fetuses larger than 8.0 cm presented tactile and covering pelage, but no studied fetus presented a fully developed covering pelage (Fig. 2). No studied specimen in advanced pregnancy stages (<15.8 cm CRL) showed tooth eruption or opened eyelids.

All associations between the external biometric measures and the CRL had a high determination coefficient ($r^2 > 0.80$, $P < 0.05$;

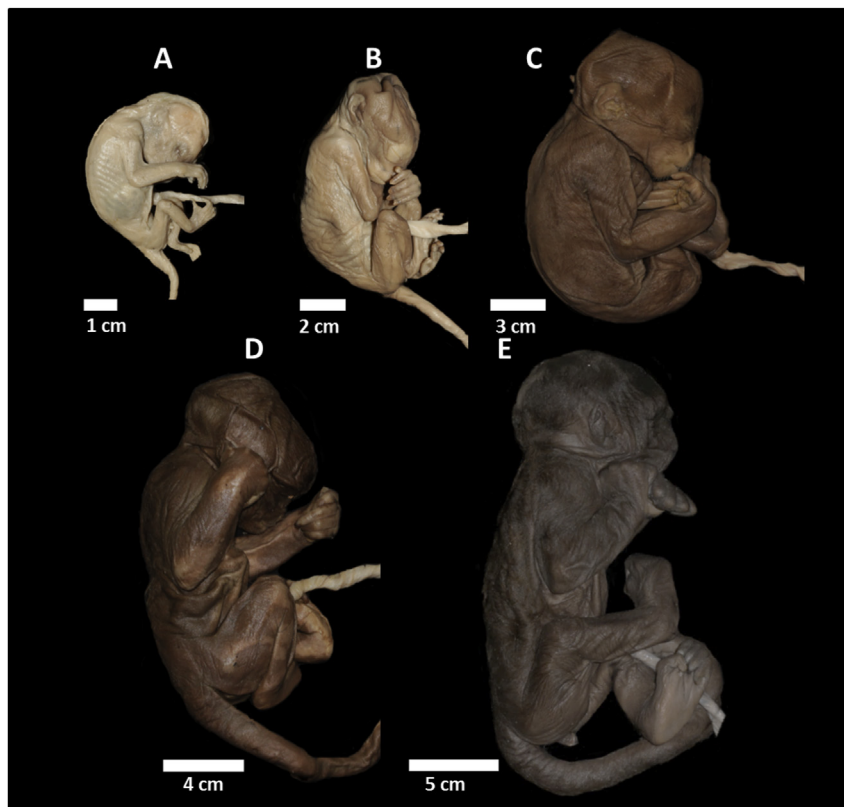


Fig. 2. Fetuses of Poeppig's woolly monkey (*Lagothrix poeppigii*) at different stages of fetal development according to crown-rump length (CRL). (A) Fetus of 4.2 cm and 7 g, presenting closed eyelids and absence of all features (skin, epidermal and mucosal pigmentation, tactile and covering pelage). (B) Fetus of 6.5 cm and 19.3 g, presenting skin and mucosal membranes with pigmentation and tactile pelage in formation. (C) Fetus with 9.6 cm and 80 g, showing covering and tactile pelage. (D) Fetus with 13.8 cm and 250 g, showing all the fetal characteristics but with closed eyelids. (E) Fetus with 17.3 cm and 410 g with all observed fetal characteristics but with closed eyelids.

Figs. 3 and 4). The body mass ($r^2 = 0.98$, $P < 0.01$), OFD ($r^2 = 0.98$, $P < 0.01$), and CC ($r^2 = 0.98$, $P < 0.01$) presented the best determination coefficients related to CRL. The allometric relationships showed strong interaction for all analyzed parameters ($r^2 < 0.90$,

$P < 0.01$). Although, the relationship between HL and FL showed a proportion of growth of approximately 1:1 ($r^2 = 0.98$, $P < 0.01$), the TL presented a faster growth than PL during the fetal phase ($r^2 = 0.96$, $P < 0.01$, Fig. 5). The growth formula used to determine

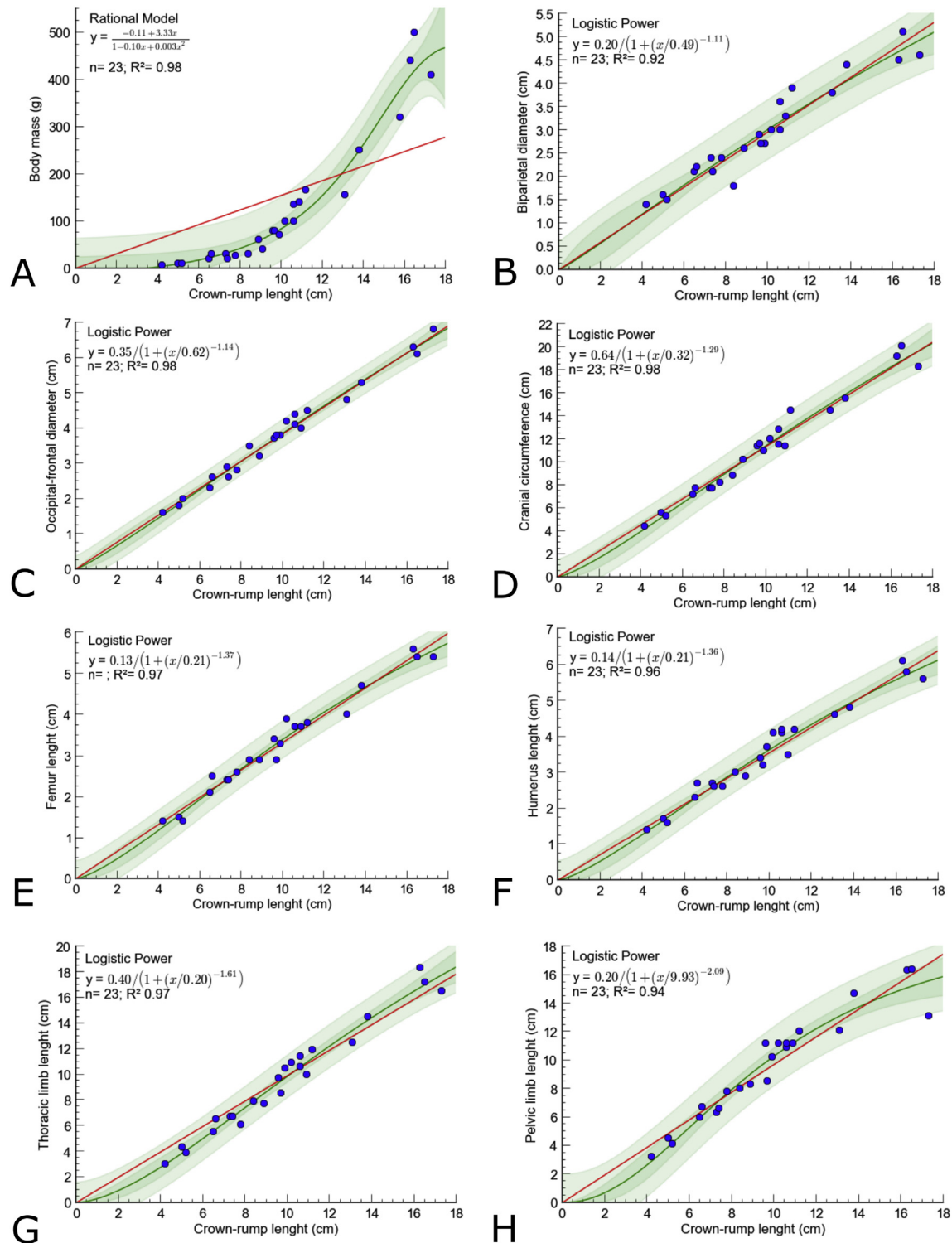


Fig. 3. Relationship between the crown-rump length (CRL) and the body mass (A), biparietal diameter (B), occipital-frontal diameter (C), cranial circumference (D), femur (E) and humerus (F) length, and length of thoracic (G) and pelvic (H) limbs in 23 Poepig's woolly monkey (*Lagothrix poeppigii*) fetuses. The green line represents the model best fitted to the plots, while the red line represents an expected linear trend with no intercept. The logistic power model was the best fitted to the measurements of the skull, thoracic limbs, and pelvic limbs, while the rational model was the best fitted to body mass. (For interpretation of the references to colour in this figure legend, the reader is referred to the Web version of this article.)

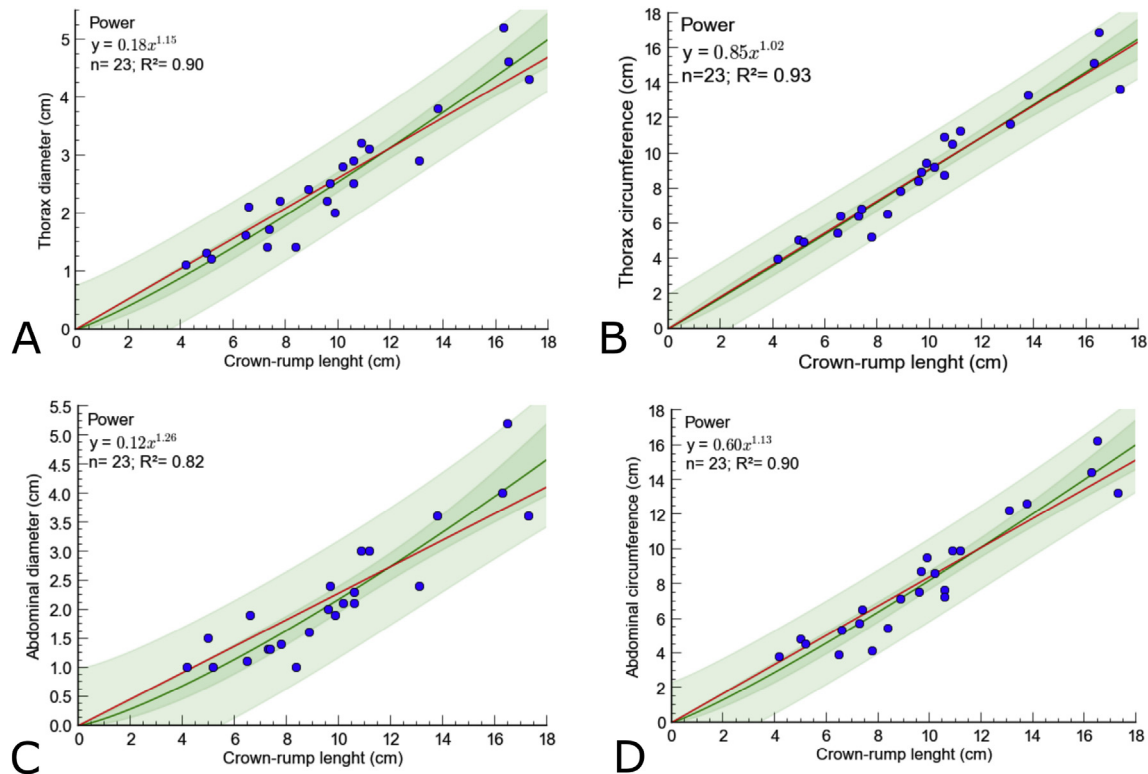


Fig. 4. Relationship between the crown-rump length (CRL) with thorax diameter (A), thorax circumference (B), abdominal diameter (C) and abdominal circumference (D), in 23 Poeppig's woolly monkey (*Lagothrix poeppigii*) fetuses. The green line represents the model best fitted to the plots, while the red line represents an expected linear trend with no intercept. The power model was the best fit for the thoracic and abdominal parameters. (For interpretation of the references to colour in this figure legend, the reader is referred to the Web version of this article.)

fetal age was $\frac{3}{W} = 0.042$ ($t = 45$). There was a high linear relationship between CRL and gestational age ($r^2 = 0.97$, $P < 0.001$; Fig. 6).

All associations between the absolute volume of internal organs and the fetal CRL showed a high determination coefficient ($r^2 \geq 0.78$, $P < 0.05$; Fig. 7). The highest associations with CRL were found for the total volume of viscera ($r^2 = 0.93$, $P < 0.01$), tubular gastrointestinal organs ($r^2 = 0.92$, $P < 0.01$), and thymus ($r^2 = 0.92$, $P < 0.01$). The relative volume of the spleen ($r = 0.07$, $r^2 = 0.005$, $P = 0.76$), the heart ($r = 0.23$, $r^2 = 0.05$, $P = 0.65$), and the lungs ($r = -0.44$, $r^2 = 0.19$, $P = 0.06$) did not show significant association with CRL (Fig. 8). In contrast, the relative volume of the tubular gastrointestinal tract ($r = 0.65$, $r^2 = 0.42$, $P = 0.003$) and the thymus ($r = 0.76$, $r^2 = 0.58$, $P = 0.0004$) had a constant increase along fetal development contrary to the relative volume of the liver ($r = -0.64$, $r^2 = 0.41$, $P = 0.004$), which showed a significant decrease. Most organs showed no differences in their relative volumes between advanced fetuses and adults (Table 2). The only significant differences between advanced fetuses and adults were observed in the thymus and the liver, with a higher and lower relative volume in the studied fetuses, respectively.

4. Discussion

Studies on the reproductive biology of wild species represent a challenge, especially due to the difficulty of keeping specimens in captivity and obtaining information in the wild [14]. In this context, this was the first study that assessed the fetal development of the wild Poeppig's woolly monkey. The results discussed here were based on gestational and postnatal data in humans, NHP, and other species.

The fetal development of external features in the woolly monkey shows that the species presents high levels of altriciality, since the covering pelage was not fully developed and we detected no open eyelids or tooth eruption in the largest fetus assessed (97.3% gestation time). An increase in pelage volume was observed in the woolly monkey between the 4th and 16th postnatal weeks, showing that these structures indeed develop after birth. The development of covering pelage is fundamental for thermal regulation of the progeny of altricial species [4]. In Rhesus monkeys (*Macaca mulatta*), thermal regulation depends on the maternal contact up to the time when the juvenile presents developed covering pelage and an autonomous central nervous system [18]. In domestic dogs and cats, neonates do not perform thermoregulation effectively until the second week after birth [19]. In contrast, in precocial species, the covering pelage is more developed before birth, such as in cattle (230 days and 81% gestational time) [20], horses (220 days and 65% gestational time) [21], and sheep (119 days and 78% gestational time) [22]. In the paca (*Cuniculus paca*), a precocial histricognath rodent, the covering pelage is fully formed on the 114th day of gestation (76.5% of gestation length) and is able to effectively aid in thermoregulation after birth [15].

Since no fetus in this study had open eyelids, we suggest that, similar to humans, this occurs during the fetal period [23], or soon after delivery [24]. Some altricial species, such as domestic dogs and cats, develop postnatal visual capacity in the extra-uterine environment, showing closed eyelids until 14 days postpartum [19,25]. In contrast, precocial species such as ruminants already have open eyelids during the final third of gestation [26].

Dental eruption was not observed in fetuses in the woolly monkey. The appearance of teeth in NHP is an important factor for the independence of the neonate because it is related to the

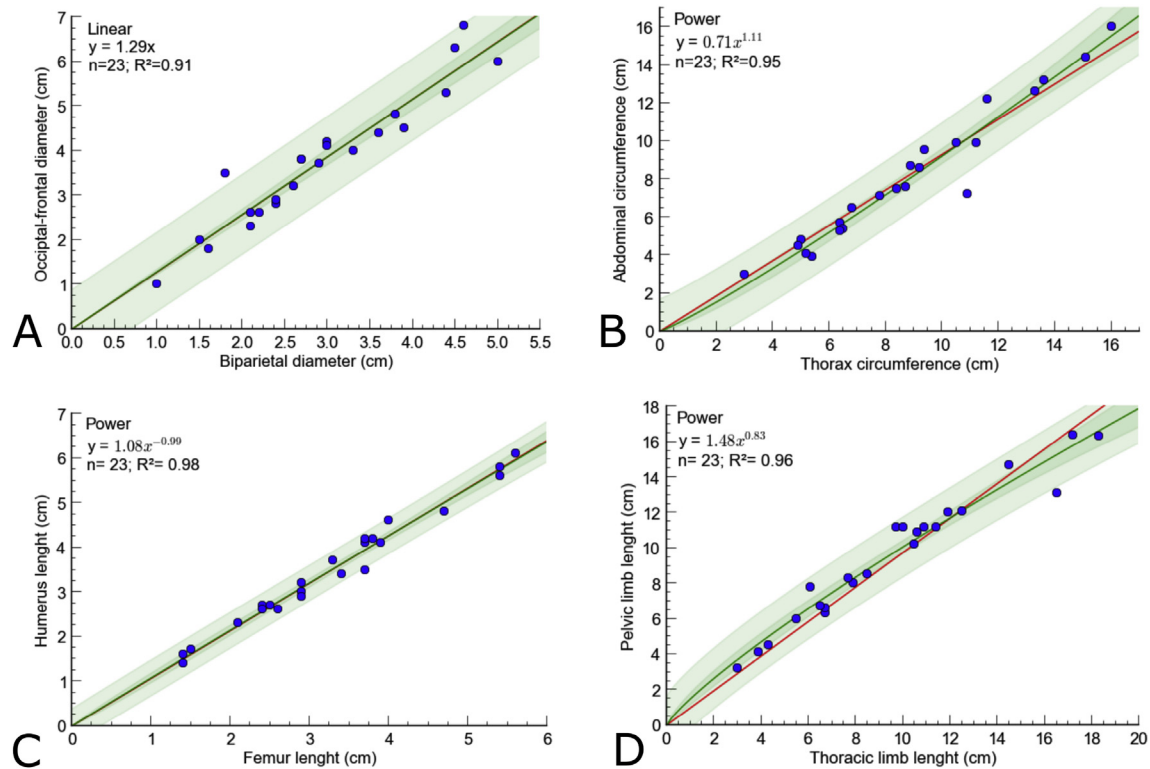


Fig. 5. Allometric relationship between the biparietal diameter versus the occipital-frontal diameter (A), the thorax circumference versus the abdominal circumference (B), the humerus versus the femur length (C), and the length of thoracic versus pelvic limbs (D) in 23 Poepig's woolly monkey (*Lagothrix poeppigii*) fetuses. The green line represents the model best fitted to the plots, while the red line represents an expected linear trend with no intercept. The logistic power model was the best fitted to the allometric relationships. (For interpretation of the references to colour in this figure legend, the reader is referred to the Web version of this article.)

ingestion of solid foods. In the captive woolly monkey, this process occurs from the 11th postnatal week onwards [4]. In this species, the second molars appear before the canines, whereas in humans the incisors are the first to erupt, at 22–24 weeks gestation (55–60% of gestational time) [27]. An increasing relationship between tooth eruption time, and body and brain mass was observed in primate species [27]. This relationship explains the usual late dental eruption in species with high parental investment and reduced numbers of offspring, which includes the Poepig's woolly monkey. In NHP species, the late tooth eruption is associated with longer weaning processes [28]. In contrast, dental eruption is

already present in fetuses of bovines (110 days, 38.9% gestational time) and sheep (105 days, 69.1% gestational time), which already have masticatory function shortly after birth [20,22].

Precocial species has a faster development of fetal morphological characteristics in comparison with altricial species [20–22]. This reproductive strategy guarantees well-developed and prepared newborns for an early independence during the extra-uterine life, allowing the reduction of the interbirth interval [15]. In contrast, the parental care in NHP implies a slower postnatal growth and a higher maternal energy [4], increasing the interval between deliveries and decreasing reproductive rates. The strategy adopted by species to maximize neonatal survival is influenced by the risk of maternal and newborn mortality. Thus, predation is an important selective pressure in natural ecosystems and also an important driving force for evolution. The predation of arboreal primates has been widely reported for various cat species and raptors [29,30]. The strategy of having a large gestation period and producing one altricial neonate [13] is usually a characteristic of a non-prey species. Primates usually deliver one neonate with a non-developed prenatal brain and muscle growth, which difficult their interpretation of environmental stimulus and motor coordination since nerve-regulated functions are not yet synchronized with the somatic growth of the individual [24]. The high maternal investment in NHPs gives to the newborn conditions to develop the necessary skills and structures to ensure postnatal survival [31–33].

Fetal biometric analyses are commonly employed in obstetric ultrasonography in NHP and are important for determining gestational age, fetal morphology, and fetal viability [8,9]. Although there was no data in the literature on birth weight of the Poepig's woolly monkeys, it was possible to estimate gestational age using the formula proposed by Huggett and Widdas [17]. The strong

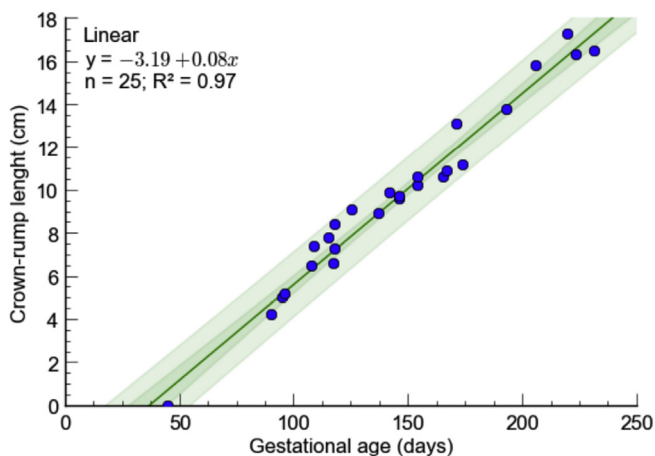


Fig. 6. Relationship between gestational age and crown-rump length (CRL) in 25 Poepig's woolly monkey (*Lagothrix poeppigii*) fetuses.

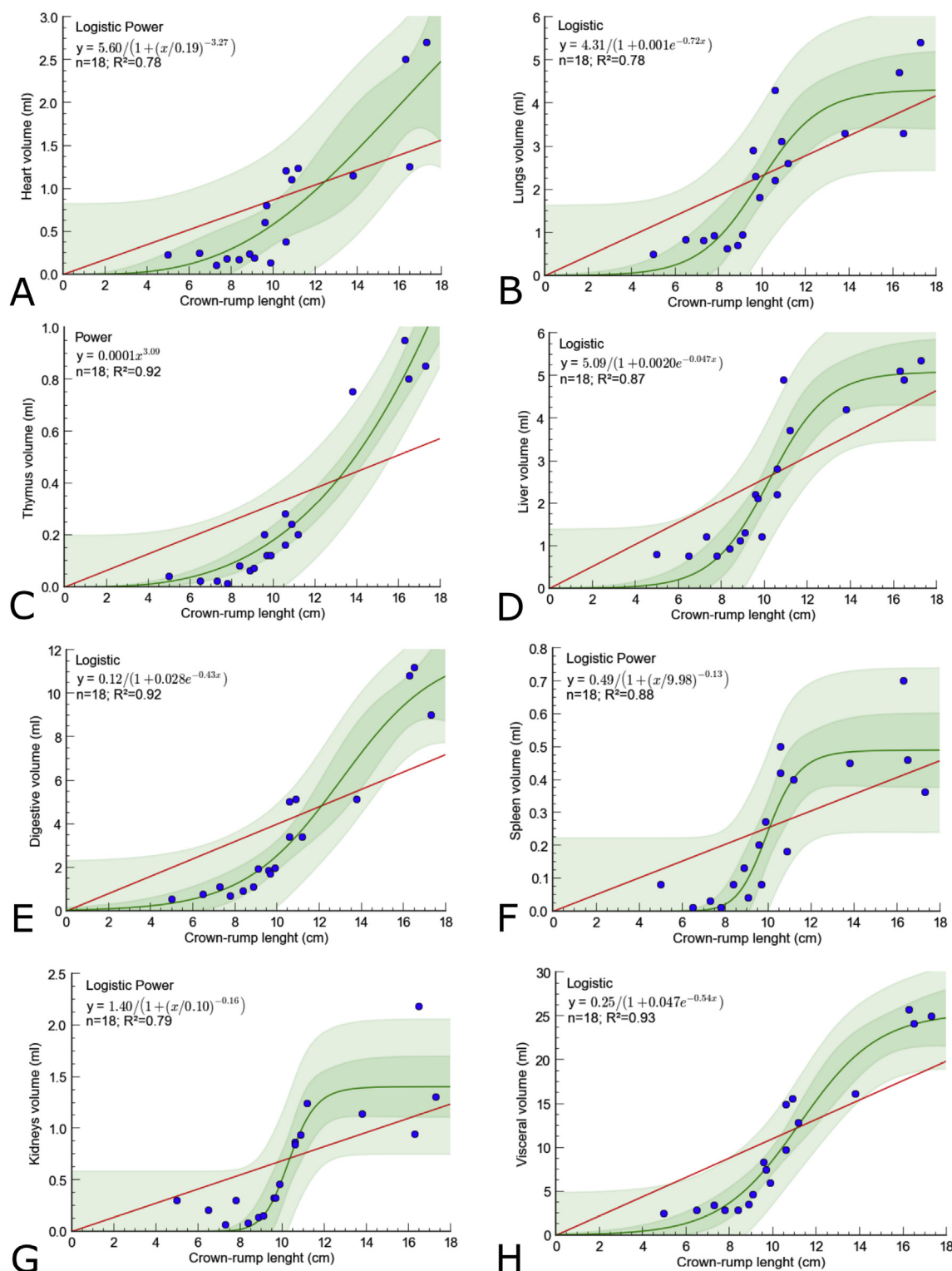


Fig. 7. Relationship between the volume of the heart (A), lungs (B), thymus (C), liver (D), digestive tract (E), spleen (F), kidneys (G), and visceral (H) tissues, with the crown-rump length (CRL) in 18 Poepig's woolly monkey (*Lagothrix poeppigii*) fetuses. The green line represents the model best fitted to the plots, while the red line represents an expected linear trend with no intercept. The logistic model was the best fitted to the volume of lungs, liver, tubular digestive, and total viscera; the logistic power model was the best fitted to the volume of heart, kidneys, and spleen; and the power model was best fitted to the thymic volume. (For interpretation of the references to colour in this figure legend, the reader is referred to the Web version of this article.)

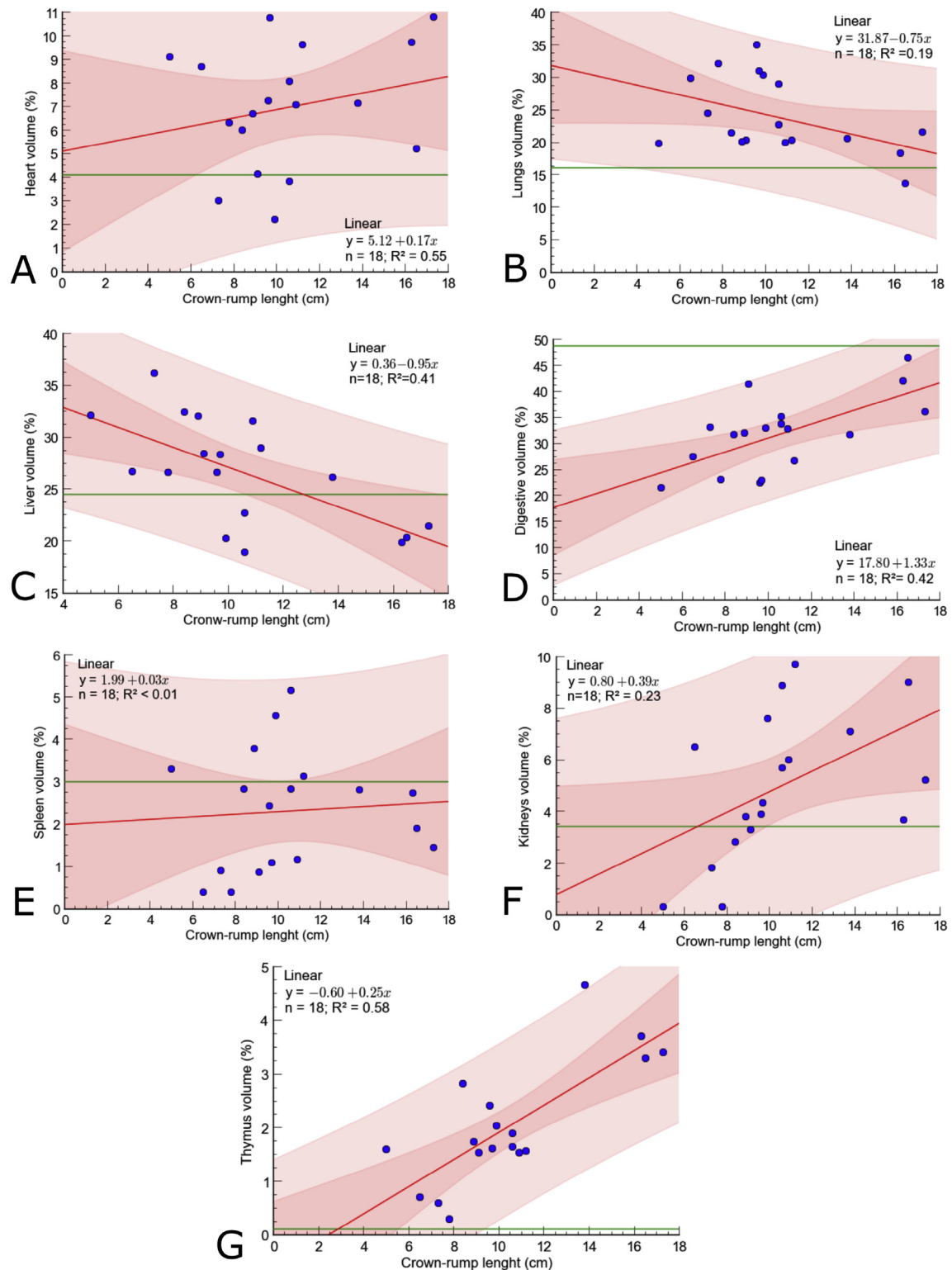


Fig. 8. Relationship between the relative volume of the heart (A), lungs (B), liver (C), tubular digestive organs (D), kidneys (E), spleen (F), and thymus (G) with respect to the crown-rump length (CRL) in 18 *Poeppig's* woolly monkey (*Lagothrix poeppigii*) fetuses. The green line represents the relative volume in adult animals, while the red line represents the linear model. (For interpretation of the references to colour in this figure legend, the reader is referred to the Web version of this article.)

relationship obtained with the CRL guarantees the reliability of this result. The relationship between CRL and BPD, DOF, CC, and AC variables in this study were similar to those described in *Sapajus apella* [12], *Macaca mulatta* and *M. fascicularis* [8].

The *Lagothrix* genus encompasses quadruped primates that are able to perform jumps and escalations, requiring a similar proportion of limb sizes [34]. The faster growth of the thoracic limbs in relation to the pelvic limbs observed in this study is non-suitable

Table 2
Absolute and relative volume of the visceral organs of Poeppig's woolly monkeys (*Lagothrix poeppigii*) in advanced pregnancy stage (CRL > 15.0 cm; n = 03) and adulthood (n = 13).

Organ	Absolute volume \pm SD (ml)		Relative volume \pm SD (%)		T value	F value	df	P value
	Fetus	Adult	Fetus	Adult				
Heart	2.15 \pm 0.78	25.56 \pm 8.4	8.58 \pm 2.97	4.11 \pm 0.9	4.30	0.09	2	0.12
Thymus	0.86 \pm 0.07	0.76 \pm 1.2	0.39 \pm 0.20	0.10 \pm 0.2	2.57	1.16	5	<0.01
Lungs	4.46 \pm 1.06	100.00 \pm 26.9	17.87 \pm 3.98	16.00 \pm 2.7	4.30	0.44	2	0.52
Liver	5.11 \pm 0.22	152.33 \pm 35.7	20.52 \pm 0.81	24.53 \pm 2.8	2.17	11.57	12	<0.01
Tubular gastrointestinal organs	10.33 \pm 1.17	302.22 \pm 63.1	41.53 \pm 5.23	48.79 \pm 4.3	3.18	0.66	3	0.11
Kidneys	1.47 \pm 0.63	21.15 \pm 4.72	5.95 \pm 2.74	3.40 \pm 0.4	4.30	0.02	2	0.24
Spleen	0.50 \pm 0.17	18.34 \pm 7.3	2.02 \pm 0.64	3.02 \pm 1.2	2.44	3.50	6	0.09
Total visceral volume	24.91 \pm 0.80	620.26 \pm 121.2	—	—	—	—	—	—

for their type of locomotion. Since the type of locomotion influences the proportion between limbs, the growth of the limbs will probably be compensated during postnatal development.

In the woolly monkey, there were no significant differences between the relative volume of internal organs in advanced fetuses larger than 15.8 cm CRL and adults, with the exception of the thymus and liver. The relative fetal hepatic volume decreased from 30 to 34% on day 90 (40% of gestational time) to 20% at the end of gestation (97.3% gestational time), and adults had a relative volume of 24%. In parallel, the tubular gastrointestinal tract presented a relative growth from 20–22%–41% during the same period, and adults had a relative volume of 24%. In humans, the liver weight accounts for 10% of fetal weight at the 9th week of gestation (25% gestation time), 5% in the neonate, and 2% in adults [35]. This decrease is explained by the maturation of hepatic tissues and the replacement of hepatic hematopoietic function by splenic and lymphoid tissues throughout fetal development [35,36]. The relative hepatic volume in the fetal period of woolly monkeys apparently occurs simultaneously with the relative growth of other systems, such as the tubular gastrointestinal tract, which grows in the postnatal period up to the proportional volume of 24% in adults.

The heart of the fetuses in the woolly monkey presents an accelerated volume increase between fetuses of 9.6 cm CRL, and 0.5 ml in organ volume (65% of gestational time) to 16 cm CRL, and 2.5 ml in organ volume (91% of gestation time). This is similar to humans, in which the organ grows 4-fold its size from the 17th week (42% of gestation time) until the end of gestation [37].

In the Poeppig's woolly monkey, the absolute increase of lung volume is similar to described for *M. nemestrina*, where a linear increase was observed in pulmonary weight related to CRL, during the 2nd and 3rd trimesters of gestation [38]. In *M. mulata*, a similar increase is also observed in the 3rd trimester [39]. The decrease in the relative volume observed in *L. poeppigii* in this study suggests a still incomplete maturation process, since the organ is non-functional during the fetal period. In humans, prenatal lung morphology undergoes complete remodeling, and in the first three years of adulthood the alveoli undergo a process that increases the area of gas exchange, giving the lung a mature morphology [40].

The spleen of the adult woolly monkey has a constant relative volume, which is maintained in adults. In humans, the spleen presents an initial important hematopoietic and immunological function between 3 and 6 months of gestation, but afterwards, the function decreases [41].

During the fetal development in the woolly monkey, the thymus presents a significant growth, reaching 4% of relative volume in the advanced fetuses, being significantly larger than the 0.1% observed in adults. In humans, the thymus is a rather functional organ and the main producer of lymphocytes in the fetal phase [42], but reduces in size around 11–15 years as the immune system matures [35].

This study describes most important morphological events of the fetal development in the woolly monkey, showing that the species produces highly altricial newborns with a slow and incomplete fetal development at birth. The reproductive strategy of the woolly monkey is compatible to a species with a low natural predation rate, low production of youngs, and low neonatal survival rate in nature, which requires for a long parental care during the postnatal period in order to guarantee the newborn independence. Since the woolly monkey is currently the most hunted Neotropical primate, and one of the most hunted mammals in the Amazon [43], its reproductive strategy suggests that this species is not adapted to respond to high hunting pressures. In addition, the data obtained is also useful to improve imaging techniques, and may contribute to the reproductive management *in situ* and *ex situ* of the most hunted primate in the Amazon.

Acknowledgments

We sincerely thank all the people from the communities in the Yavarí-Mirín River, without whom this work would not be possible. This work was supported by the Foundation for Research Support of Pará (FAPESPA, protocol 005/2015), the National Council of Technological and Scientific Development (CNPq, protocol 452908/2016–7 and 201475/2017–0), the Earthwatch Institute, the IVITA (Instituto Veterinario de Investigaciones de Trópico y de Altura), and the Museo de la Universidad Nacional de la Amazonía Peruana (UNAP). We would like to thank Mr. Walfrido Monteiro (<https://www.behance.net/WalfridoMonteiro>) for his wonderful video produced with 3D fetal images attached as supplementary material of this paper.

Appendix A. Supplementary data

Supplementary data related to this article can be found at <https://doi.org/10.1016/j.theriogenology.2017.12.022>.

References

- [1] Stevenson P, Link A, Di-Fiore A, De-La-Torre S, Boubli JP. *Lagothrix poeppigii*: The IUCN Red List of Threatened Species 2008. <https://doi.org/10.2305/IUCN.UK.2008.RLTS.T39927A10290256.en>.
- [2] Mooney JC, Lee PC. Reproductive parameters in captive woolly monkeys (*Lagothrix lagotricha*). *Zoo Biol* 1999;18:421–7.
- [3] Williams L. Breeding Humboldt's woolly monkey (*Lagothrix lagotricha*) at murrayton woolly monkey sanctuary. *Int Zoo Yb* 1967;1:86–8.
- [4] Mack D, Kafka H. Breeding and rearing of woolly monkeys *Lagothrix lagotricha* at the national zoological park, Washington. *Int Zoo Yb* 1978;1:117–22.
- [5] Mayor P, Bowler M, López-Plana C. Anatomicohistological characteristics of the tubular genital organs of the female woolly monkey (*Lagothrix poeppigii*). *Am J Primatol* 2012;74(11):1006–16.
- [6] Sousa FCA, Alves FR, Fortes EAM, Ferraz MS, Machado-Júnior AAN, Menezes DJA, et al. Pregnancy in Hystricomorpha: gestational age and embryonicfetal development of agouti (*Dasyprocta prymnolopha*, Wagler 1831) estimated by ultrasonography. *Theriogenology* 2012;78:1278–85.

- [7] Winkelmann CJ, Krause SM, McCracken PJ, Brammer DW, Gelovani JG. Imaging in research using nonhuman primates, in *Nonhuman Primates*. In: Abee CR, Mansfield K, Tardif SD, editors. Biomedical research: diseases; 2012. p. 795–815. London: Timothy Morris.
- [8] Tarantal AF, Hendrickx AG. Characterization of prenatal growth and development in the crab-eating macaque (*Macaca fascicularis*) by ultrasound. *Anat Rec* 1988;222:177–84.
- [9] Devonald KJ, Harewood WJ, Ellwood DA, Phippard AF. Fetal ultrasonography: normal biometric ranges in the baboon (*Papio hamadryas*). *J Med Primatol* 1996;25:339–45.
- [10] Tarantal AF. Chapter 20: ultrasound imaging in rhesus (*Macaca mulatta*) and long-tailed (*Macaca fascicularis*) macaques: reproductive and research applications. In: Wolfe-Coote S, editor. The laboratory primate. London: Elsevier; 2005. p. 317–49.
- [11] Bourry O, Boyer OOMO, Blanchard A, Rouquet P. Fetal ultrasonography: biometric data from four African primate species. *J Med Primatol* 2006;35:38–47.
- [12] Corradini P, Recabarren M, Seron-Ferré M, Parraguez VH. Study of prenatal growth in the capuchin monkey (*Cebus apella*) by ultrasound. *J Med Primatol* 1998;27:287–92.
- [13] Bowler M, Anderson M, Montes D, Pérez P, Mayor P. Refining reproductive parameters for modelling sustainability and extinction in hunted primate populations in the Amazon. *PLoS One* 2014;9(4):1–8.
- [14] Mayor P, El Bizri H, Bodmer R, Bowler M. Assessment of mammal reproduction for hunting sustainability through community-based sampling of species in the wild. *Conserv Biol* 2017;31(4):912–23.
- [15] El Bizri HR, Monteiro FOB, Andrade RS, Valsecchi J, Guimarães DAA, Mayor P. Embryonic and fetal morphology in the lowland paca (*Cuniculus paca*): a precocial hystricomorph rodent. *Theriogenology* 2017;104:7–17.
- [16] International Committee on Veterinary Embryological Nomenclature. *Nomina embryologica veterinaria*. Zurich, Ithaca, New York: World Association of Veterinary Anatomists (WAVA); 1994.
- [17] Huggett AG, Widdas WF. The relationship between mammalian foetal weight and conception age. *J Physiol* 1951;114(3):306–17.
- [18] Harlow HF, Suomi SJ. Nature of love-simplified. *Am Psychol* 1970;25(2):161–8.
- [19] Domingos TCS, Rocha AA, Cunha ICN. Cuidados básicos com a gestante e o neonato canino e felino: revisão de literatura. *JBCA* 2008;2(1):94–120.
- [20] Salisbury GW, Van Denmark NL, Lodge JR. *Physiology of reproduction and artificial insemination of cattle*. San Francisco: Freeman and Company; 1978.
- [21] Douglas RH, Ginther OJ. Development of equine fetus and placenta. *J Reprod Fertil Suppl* 1975;23:503–5.
- [22] Cloete JHL. Prenatal growth in the Merino sheep. *Onderstepoort J Vet Sci Anim Ind* 1939;13(2):417–557.
- [23] Byun TH, Kim JT, Park HW, Kim WK. Timetable for upper eyelid development in staged human embryos and fetuses. *Anat Rec* 2011;5:789–96.
- [24] Cummings JR, Muchlinski MN, Kirk EC, Rehorek SJ, DeLeon VB, Smith TD. Eye size at birth in prosimian primates: life history correlates and growth patterns. *PLoS One* 2012;7:1–15.
- [25] Prats A, Prats A. *Neonatologia e pediatria: canina e felina*. São Paulo: Interbook; 2005.
- [26] DesCôteaux L, Gnemmi G, Colloton J. *Practical atlas of ruminant and camelid reproductive ultrasonography*. USA: Blackwell Publishing; 2010.
- [27] Henderson H. Platyrrhine dental eruption sequences. *Am J Phys Anthropol* 2007;134(2):226–39.
- [28] Godfrey LR. Chapter 03: general anatomy. In: Wolfe-Coote S, editor. The laboratory primate. London: Elsevier; 2005. p. 29–43.
- [29] Zuberbühler K, Jenny D. Leopard predation and primate evolution. *J Hum Evol* 2002;43(6):873–86.
- [30] Gil da Costa R, Palleroni A, Hauser MD, Touchton J, Kelley JP. Rapid acquisition of an alarm response by a neotropical primate to a newly introduced avian predator. *Proc Bio Sci* 2003;270:605–10.
- [31] Garber PA, Leigh SR. Ontogenetic variation in small-bodied New World primates: implications for patterns of reproduction and infant care. *Folia Primatol* 1997;68(1):1–22.
- [32] Leigh SR. Brain growth, life history, and cognition in primate and human evolution. *Am J Primatol* 2004;62(3):139–64.
- [33] Hart D. Predation on Primates: a biogeographical analysis. In: Nekaris KAI, Gursky-Doyen S, editors. *Primate anti-predator strategies*. Iowa: Springer-Verlag; 2007. p. 27–59.
- [34] Cant JG, Youlatos D, Rose MD. Locomotor behavior of *Lagothrix lagothricha* and *Ateles belzebuth* in Yasuni National Park, Ecuador: general patterns and non-suspensory modes. *J Hum Evol* 2001;41(2):141–66.
- [35] Kliegman RM, Behrman RE, Jenson HB, Stanton B. Nelson: tratado de pediatria. Rio de Janeiro: Elsevier; 2009.
- [36] Guyton AC, Hall JE. *Tratado de Fisiologia Médica*. Rio de Janeiro: Guanabara Koogan; 2017.
- [37] Cavalcanti JS, Duarte SM. Estudo morfométrico do coração fetal: sua utilização como parâmetro para análise ecocardiográfica. *Radiol Bras* 2008;41(2):99–101.
- [38] Hodson WA, Palmer S, Blakely GA, Murphy JH, Woodrum DE, Morgan TE. Lung development in the fetal primate *Macaca nemestrina*. I. Growth and compositional changes. *Pediatr Res* 1977;11:1009–14.
- [39] Perelman RH, Engle MJ, Palta M, Kemnitz JW, Farrell PM. Fetal lung development in male and female nonhuman primates. *Pediatr Res* 1986;20:987–91.
- [40] Burri PH. Fetal and postnatal development of the lung. *Annu Rev Physiol* 1984;46:617–28.
- [41] Holt PG, Jones CA. The development of the immune system during pregnancy and early life. *Allergy* 2000;55(8):688–97.
- [42] Rajeswari PDR, Aruna K, Sankar R. Comparative morphological and anatomical study on thymus gland of human and primate. *Int J Anat Res* 2014;2(3):507–10.
- [43] Mayor P, Pérez-Peña P, Bowler M, Puertas P, Kirkland M, Bodmer R. Effects of selective logging on large mammal populations in a remote indigenous territory in the northern Peruvian Amazon. *Ecol Soc* 2015;20(4):36.